

# **Cirrus™ HD-OCT**

**Details define  
your decisions**









# With high-definition OCT- Carl Zeiss Meditec takes you beyond standard spectral domain


Built on 10 years experience at the vanguard of innovation, Carl Zeiss Meditec OCT technology has become the recognized standard of care. Now, Cirrus HD-OCT offers another leap forward with a superior platform that delivers unprecedented imaging details for clinical decision making.

- ZEISS optics provide superior visualization of anatomical details across a wider range of patients
- Robust engineering with premium components ensures consistent precision performance
- Unique HD layer maps and images highlight clinically relevant details for identification and monitoring of specific diseases – all at a glance




## HD layer map of ILM

See the distortion of the inner limiting membrane associated with vitreomacular traction



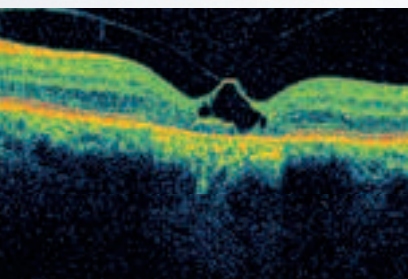

## HD layer map of RPE

Observe the retinal pigment epithelial elevation with pigment epithelial detachment



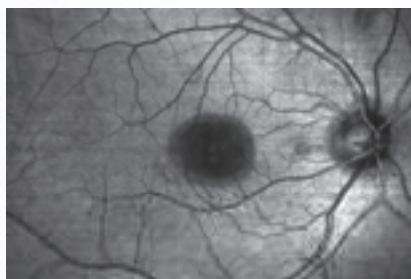
## HD retinal thickness map

Identify the edema associated with epiretinal membrane



**HD cross-sectional image**

Examine the fine details of the retinal layers



**HD fundus image**

Review the exquisitely detailed fundus image to know the precise location of pathology and placement of scan





## **Immerse yourself in the image**

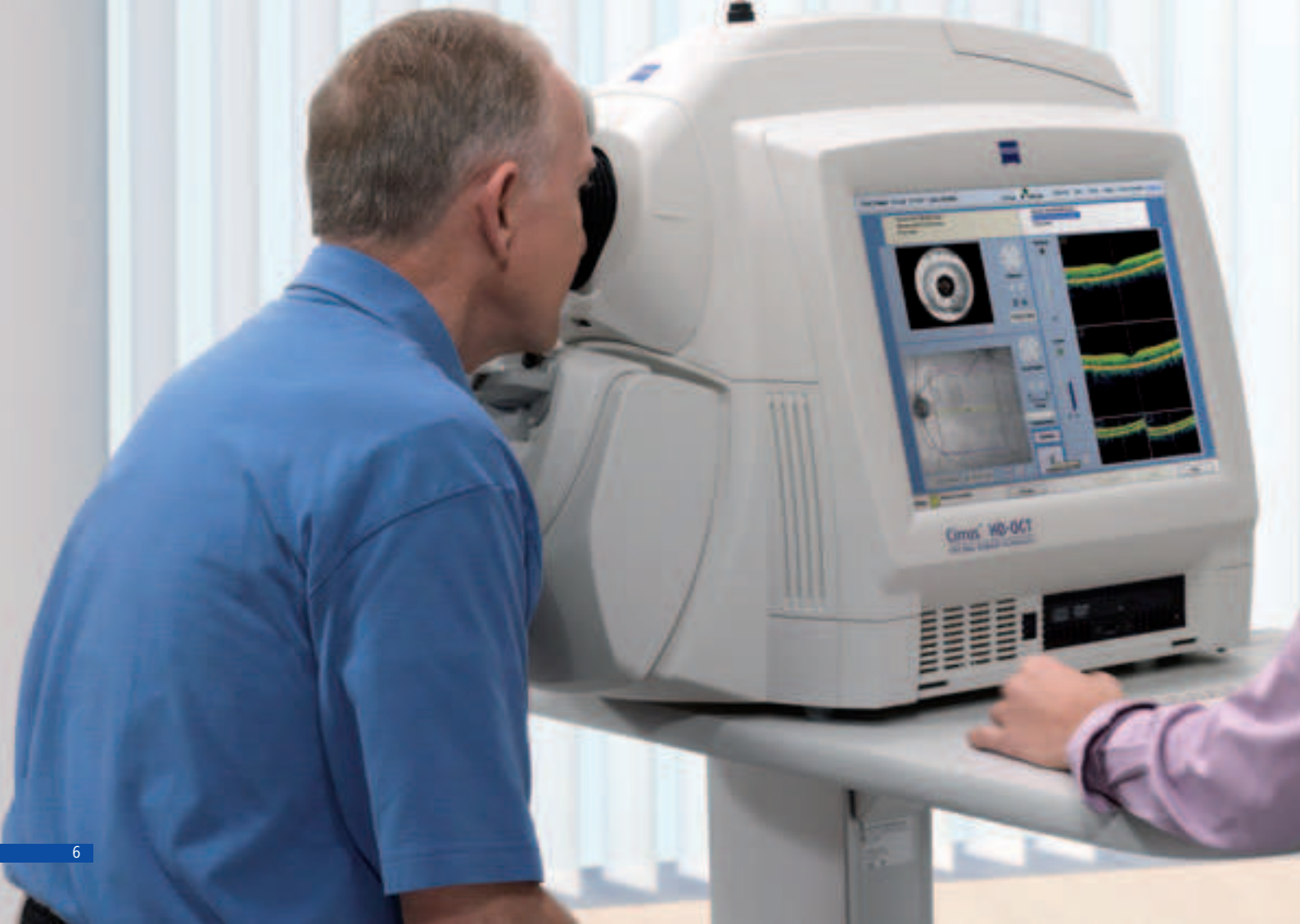Some views draw the observer directly into the picture – views such as those offered by Cirrus HD-OCT. This new high-performance OCT instrument from Carl Zeiss Meditec offers a quantum leap forward. Featuring spectral domain technology, Cirrus HD-OCT delivers exquisite high-definition images of the ocular structures. For the first time, immerse yourself in truly grand views.

## Discover Real-Time Registration

**Cirrus HD-OCT enables repeatable visualization of clinically relevant anatomy with exact correlation between the OCT scan and the fundus image. Comprehensive navigational tools ensure efficient and simple operation.**

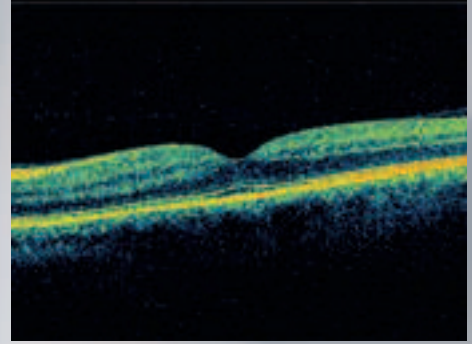
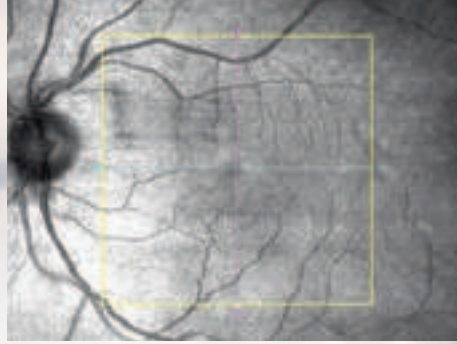
### **Designed for efficiency**

- Small footprint and integrated design are ideal for crowded or busy practice
  - 90 degree orientation facilitates observation of patient throughout exam
  - Advanced optics aid in the examination of patients with cataracts. Dilation is not required even for pupils as small as 2.5 mm
- Mouse Driven Alignment™ delivers superior image capture and analysis in just a few clicks, resulting in reduced chair time for the patient
  - Auto Patient Recall™ assures patient position and instrument setting are repeated from previous visit

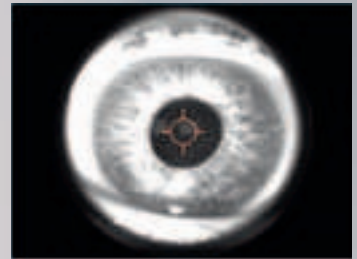




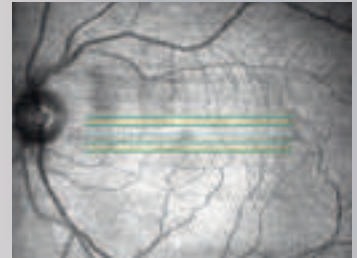
*Simultaneous capture of fundus image and OCT image provides exact Real-Time Registration™*



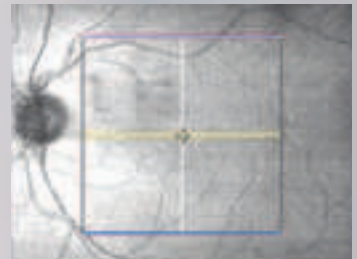
*Iris viewer provides clear visualization of the pupil for simple Mouse Driven Alignment™*



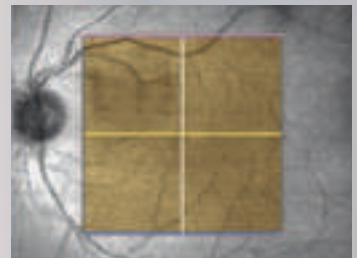*Line scanning ophthalmoscope (LSO) allows for accurate and specific targeting of pathology creating beautiful high-quality fundus images*



*Live Precision Targeting™ enables the operator to move the scan box within the 30° x 36° field of view without adjusting patient fixation*




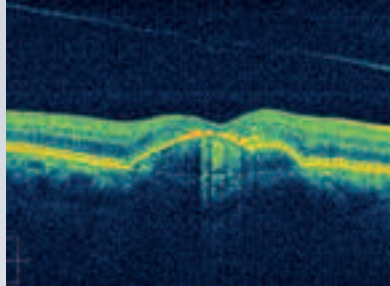
*Visit-to-visit registration with overlay of the fundus image from the previous scan assures reproducibility*



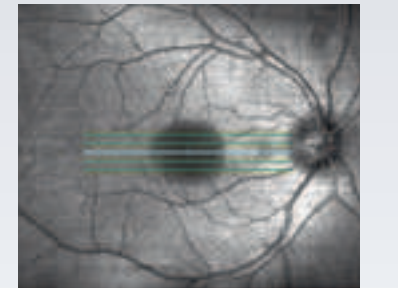
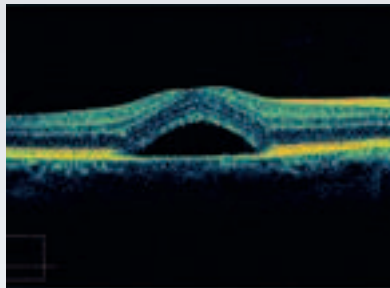
# Breathtaking Details

Cirrus HD-OCT provides uniquely detailed HD maps and images that come from advanced analyses and next generation precise algorithms.


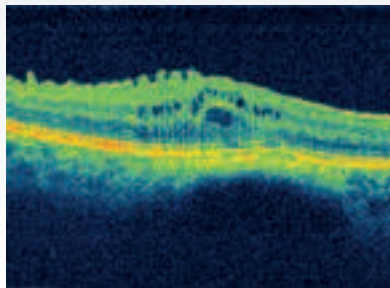
## Age-Related Macular Degeneration



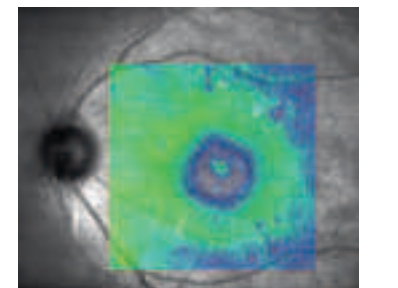
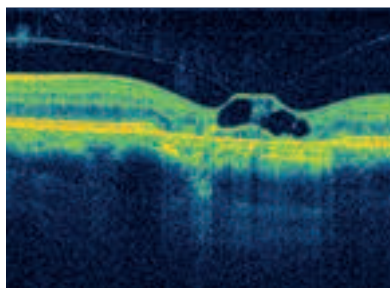
## Central Serous Chorioretinopathy



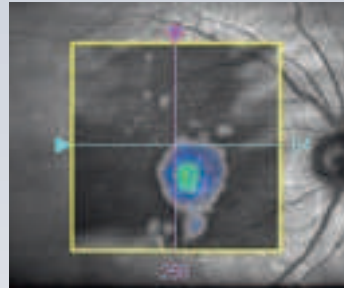

## Epiretinal Membrane



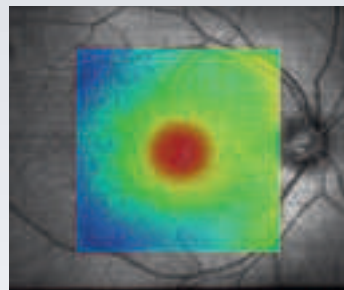

## Vitreomacular Traction with Geographic Atrophy



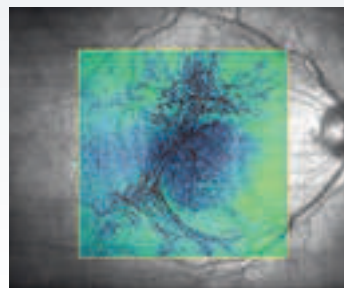
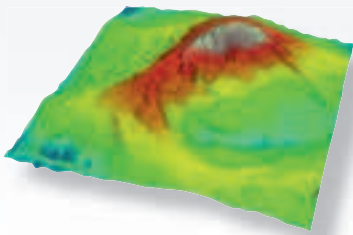




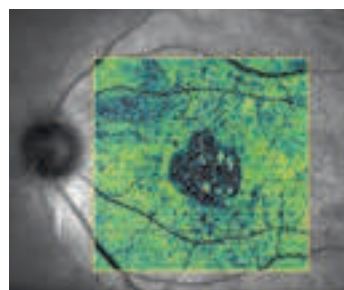

- HD OCT image is a high-definition cross-sectional view that reveals subtle details of pathology
- HD RPE layer map displays the extent of the sub-foveal lesion and location of drusen
- HD ILM layer map shows the foveal pit is still present
- RPE deviation map aligns RPE disturbances to the fundus, using RPE-RPE fit map



- HD OCT image reveals the retinal layers in exquisite detail. Exact location of this image is indicated on LSO fundus image
- LSO fundus image indicates fluid buildup and shows distinct features of retinal vasculature
- HD thickness map displays irregularity of retinal thickness
- Thickness map overlay demonstrates how the thickening relates to the fundus



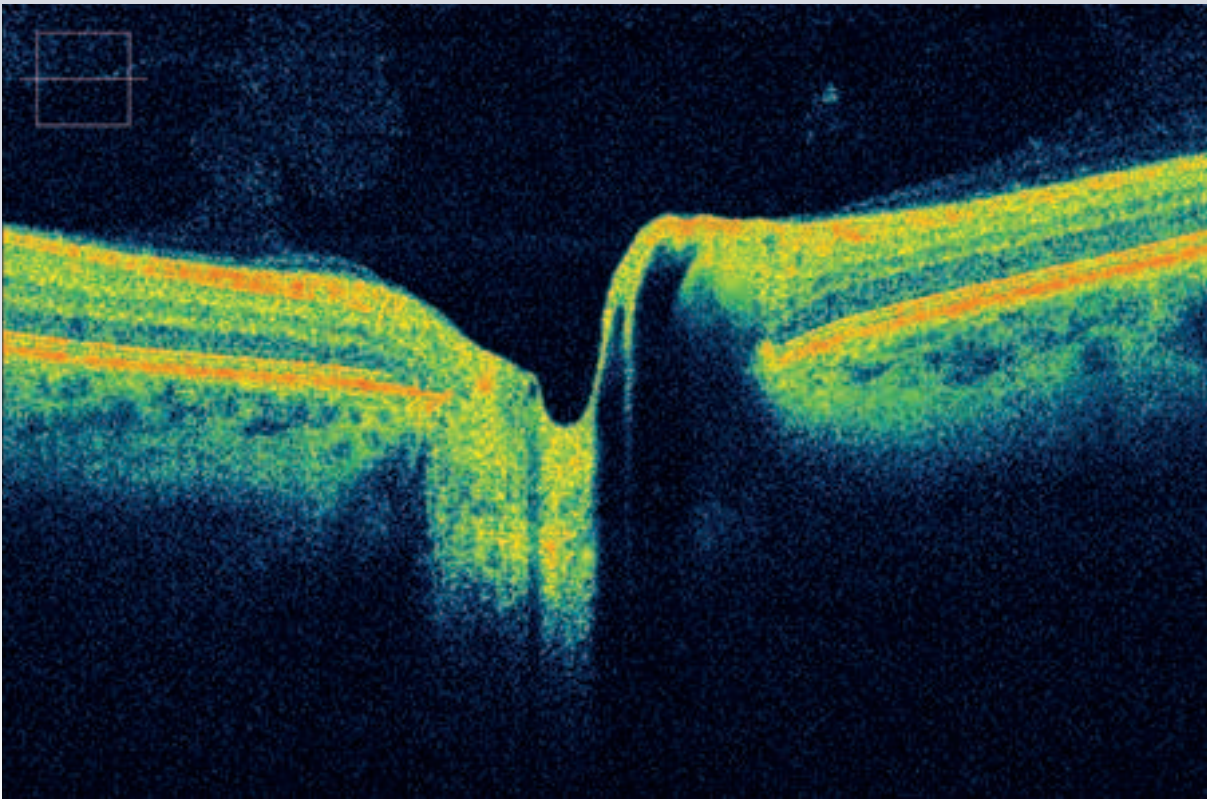
- HD OCT image shows deformation of the normal retinal contour
- HD ILM layer map displays puckering of the ILM caused by traction from the ERM
- HD thickness map indicates thickening of retinal tissue
- Tissue layer overlay demonstrates the extent of the ERM aligned with the fundus



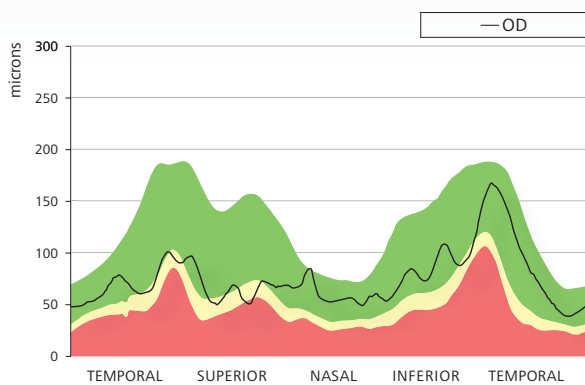
- HD OCT image shows attachment of the posterior hyaloid to the fovea and contortion of the retinal tissues
- Fundus image with thickness map overlay relates the fundus image to the underlying condition
- HD ILM layer map shows cylindrical distortion from traction on ILM
- Tissue layer overlay allows you to see the area where reflectivity properties have changed due to disruption of photoreceptors

# Know the Precise Location

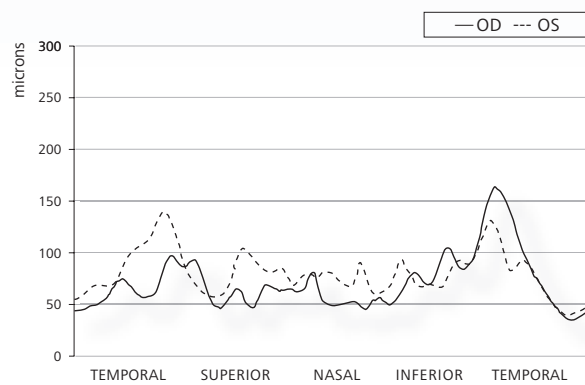
Unique registration algorithm assures accurate and precise location of peripapillary circle for RNFL analysis



HD OCT image provides high-definition, high-resolution cross-sectional image of the optic nerve head



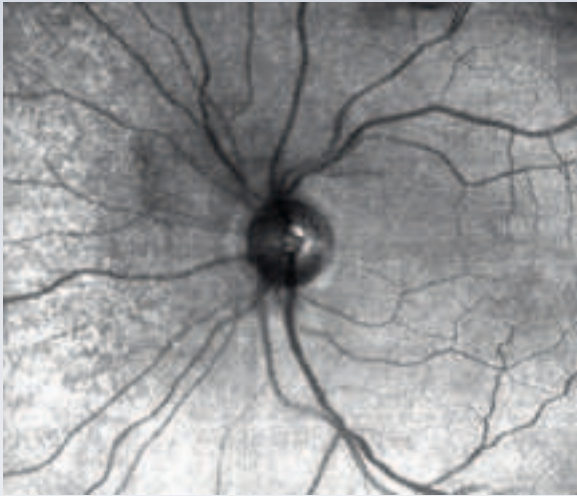
TSNIT graph plots RNFL thickness and compares it to a normative database



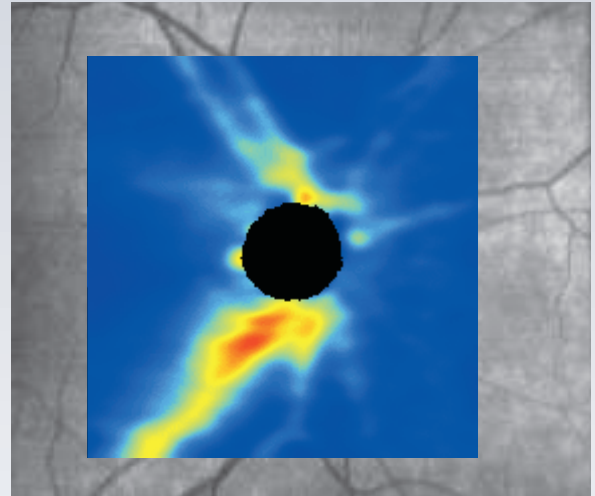
OU TSNIT graph displays RNFL thickness of both eyes for identification of asymmetry



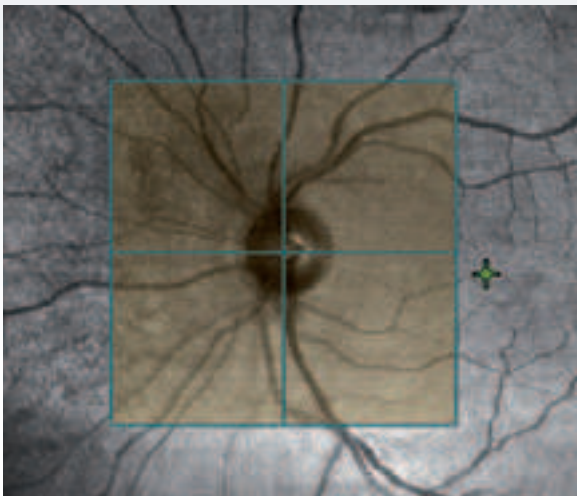**High-definition data acquisition and advanced analysis provide precise registration and excellent reproducibility critical for glaucoma detection and management**



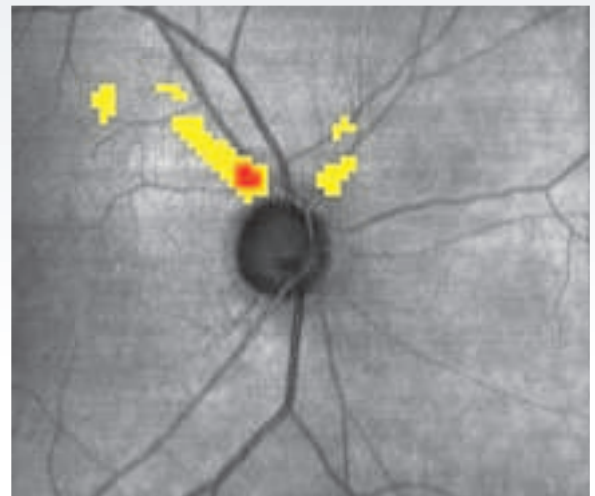
*LSO provides an exquisite fundus image for visualization of the optic nerve head*



*RNFL thickness map presents the pattern and thickness of the nerve fiber layer and aids in the detection of pattern defects*



*LSO with OCT fundus overlay from previous visit demonstrates visit-to-visit registration, assuring excellent reproducibility*



*Deviation map, overlaid on OCT fundus image, illustrates where RNFL thickness deviates from a normal range*

# At a Glance: Critical Details

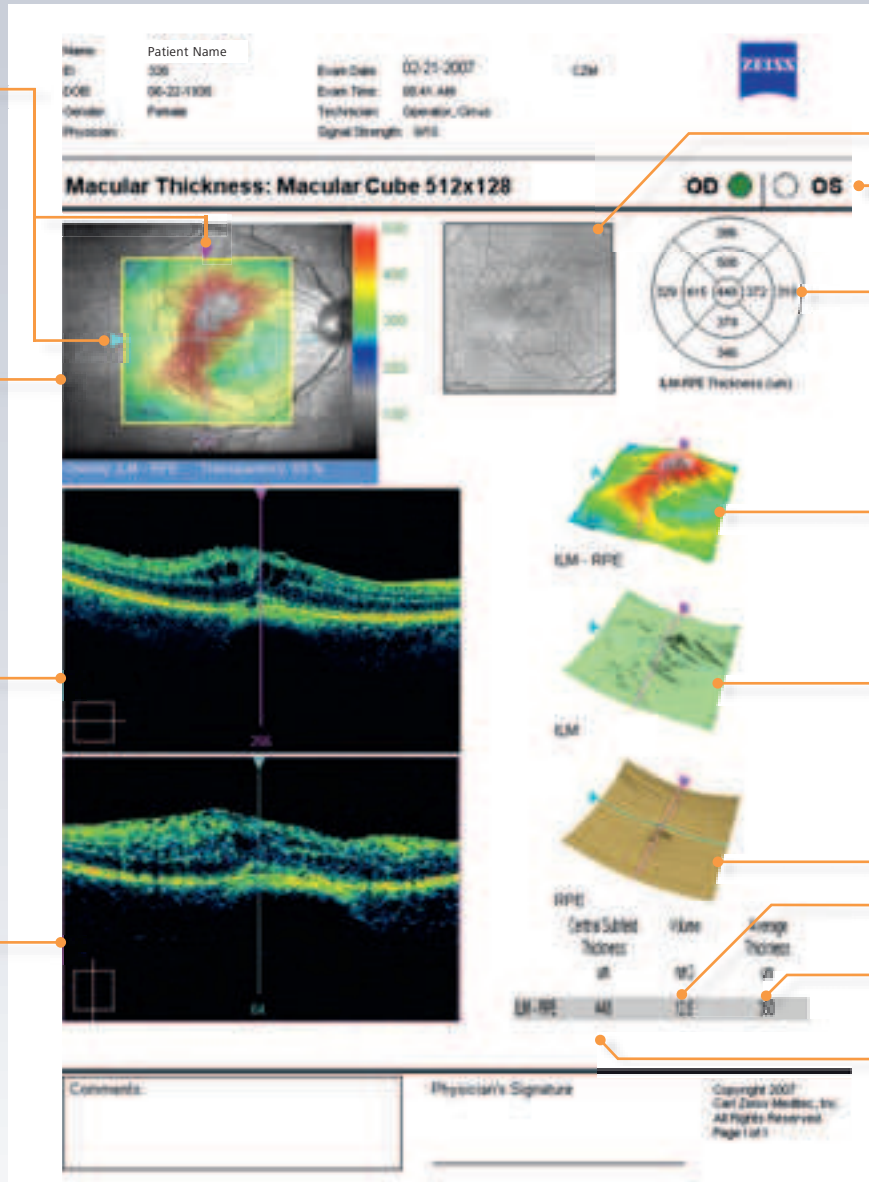
## Macular Thickness Report

Slide Navigator™ enables a simultaneous view of a selected point on LSO image, OCT fundus image, HD thickness map, HD layer maps, and HD OCT image displays

HD fundus image, here shown with ILM-RPE retinal thickness map overlay

Framed in blue, this image corresponds to the horizontal crosshair line on fundus image above

Framed in pink, this image corresponds to vertical crosshair line on fundus image above



HD OCT fundus image

Right/Left eye indicator

Macular thickness values, from ILM to RPE, in microns

HD thickness map

HD ILM layer map

HD RPE layer map

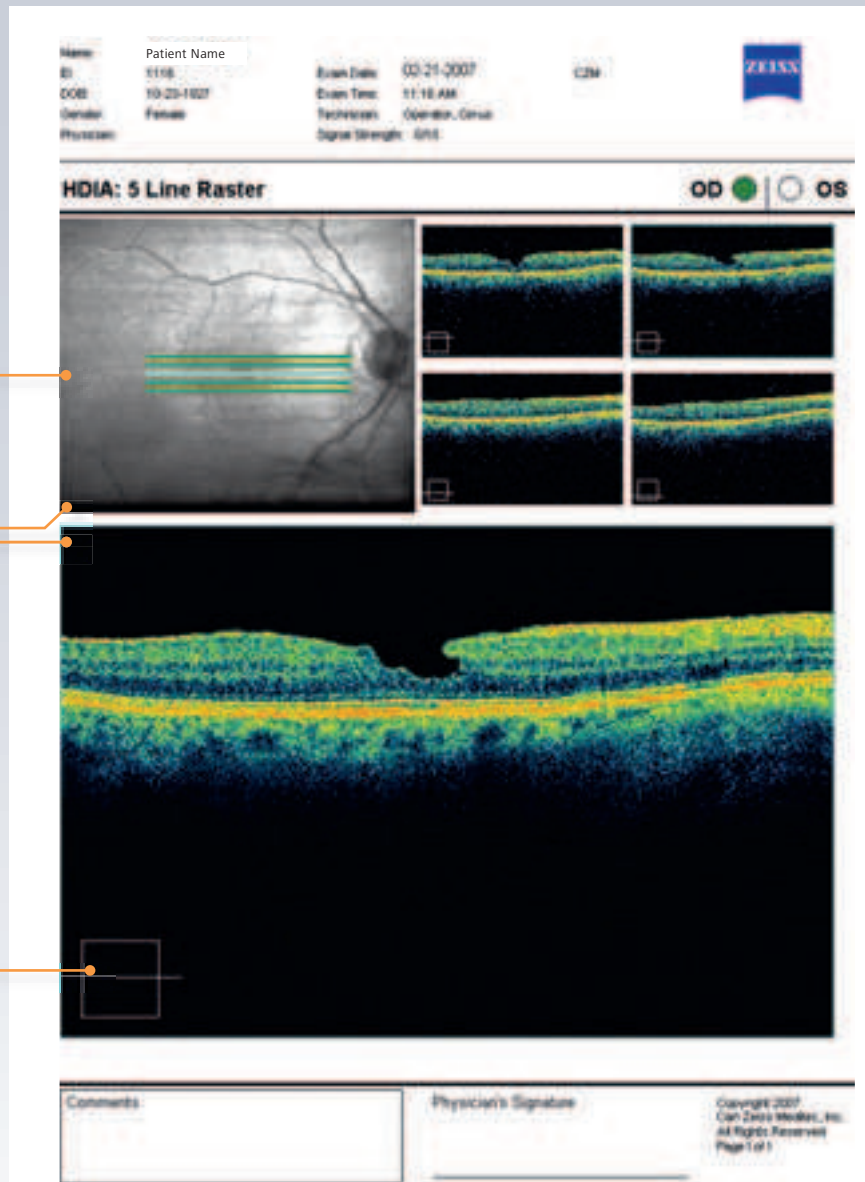
Macular volume, in cubic millimeters

Average macular thickness, in microns

Central subfield thickness, in microns



## High-Definition Image Analysis Report



Exact placement of scan lines can be seen on HD fundus image

Scan line shown in blue corresponds with image selected and displayed in enlarged view

Legend on each scan image indicates which of the 5 scan lines is displayed

## Custom Report

**Name:** Patient Name  
**ID:** 1115  
**DOB:** 06/05/1925  
**Gender:** Female  
**Physician:**  
**Exam Date:** 07-21-2007  
**Exam Time:** 10:26 AM  
**Technician:** Operator, Ghazi  
**Signal Strength:** 910

**Custom Report; Macular Cube 512x128 Combo** OD  OS

**Blue line on horizontal and vertical OCT images corresponds with exact location of tissue layer which is mapped and displayed on the right**

**Tissue layer map**

**The companion fundus image for an HD OCT image shows the precise position of the displayed scan**

**HD OCT image**

**When a fundus image with overlay is displayed, an information text box is provided**

**Overlay Description**  
 LM - RPE  
 Transparency: 36%

**Fundus image with overlay**

**Comments**  
**Physician's Signature**  
 Copyright 2007  
 Carl Zeiss Meditec, Inc.  
 All Rights Reserved  
 Page 1 of 1

The custom print mode generates a single page or multi-page report of selected scan, fundus, and fundus overlay images from any advanced interactive analysis screen. Each selection is displayed with a description or companion image for orientation